**Back Anatomy for Back Care**

The spine's structure enables us to stand, move about, bend, twist, carry things and much more. It also protects to the spinal cord and is the main pathway connecting our brain to our peripheral nervous system. When considering back-care, we can look to several different types of tissues in our backs:

1. **<u>The 33 Vertebra</u>** that comprise our spinal column

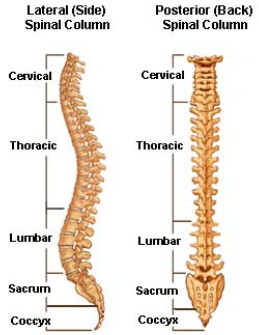


- Cervical spine: 7 vertebrae (C1–C7)
- Thoracic spine: 12 vertebrae (T1–T12)
- Lumbar spine: 5 vertebrae (L1–L5)
- Sacrum: 5 (fused) vertebrae (S1–S5)
- Coccyx: 4 (3–5) (fused) vertebrae (Tailbone)

2. The intervertebral discs

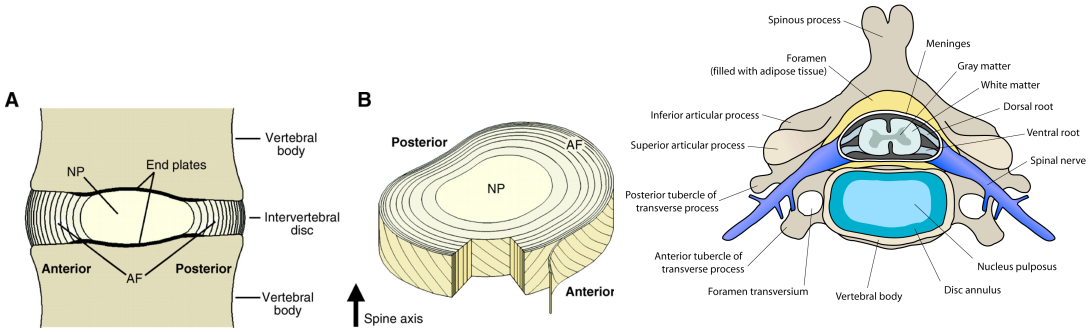


Intervertebral discs lie between adjacent vertebrae in the vertebral column. Each disc forms a fibrocartilaginous joint (a symphysis) which allows slight movement of each vertebrae while also holding the vertebrae together.

The 23 spinal discs are made up of two main aspects: an outer supportive, cartilagenous, "rubbery" ring, called the annulus fibrosus, and an inner jelly-like center, the nucleus pulposus. This structure helps distribute pressure evenly across the disc to absorb shock throughout the spine. And, as you recall, the discs are the remnants of the notochord. There's one disc between each pair of vertebrae, except for the atlas which rings the cone-shaped upward extension of the axis. The axis acts as a post around which the atlas rotates.

A spinal disc herniation, commonly referred to as a slipped disc, can happen when unbalanced mechanical pressures substantially deform the anulus fibrosus, allowing part of the nucleus to obtrude. This may happen during physical activity, trauma, or as a result of chronic deterioration related often to poor posture. The disc is not physically "slipped"; it bulges, usually in just one direction.

Both the deformed anulus and the gel-like material of the nucleus pulposus can be forced laterally, or

posteriorly, distorting local muscle function, and putting pressure on a nearby nerve (nerve root entrapment). Symptoms can vary between parasthaesia (burning, pricking sensations), numbness, chronic and/or acute pain like in sciatica, either locally or along the dermatome of the entrapped nerve, loss of muscle tone, and decreased performance.

Aging causes the nucleus pulposus to dehydrate thus limiting the disc's ability to absorb shock. This general shrinking of disc size is partially responsible for the common decrease in height as humans age. Also, the anulus fibrosus weakens with age increasing its risk of tearing.

### 3. <u>The Spinal Ligament</u>

Ligaments are fibrous bands of connective tissue linking two or more bones. One or more ligaments provide joint stability and prevent excessive movement in various specific directions. The three most important ligaments in the spine are the Ligamentum Flavum, the Anterior Longitudinal, Ligament, and the Posterior Longitudinal Ligament.

Ligamentum Flavum - forms a cover over the dura mater (tough mother), a covering that protects the spinal cord. It connects under the facet joints to create a small set of curtains over the posterior openings between the vertebrae.

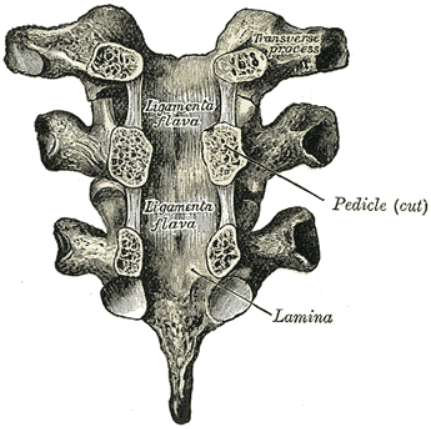


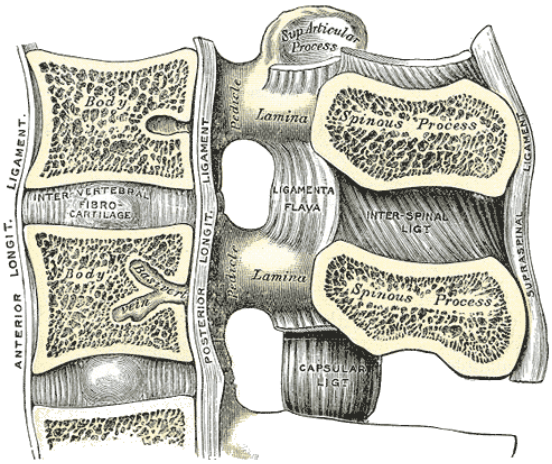


- Anterior Longitudinal Ligament - attaches to the front of each vertebra and runs longitudinally along the spine.

- Posterior Longitudinal Ligament - Ligament runs up and down behind the vertebral bodies inside the spinal canal.

**Primary Spinal Ligaments Include:**

| Ligament | Spinal Region | Limits… |
|---|---|---|
| Alar | Axis – skull | Head rotation & lateral flexion |
| Anterior Atlantoaxial | Axis & Atlas | Extension |
| Posterior Atlantoaxial | Axis & Atlas | Flexion |
| Ligamentum Nuchae | Cervical | Flexion |
| **Anterior Longitudinal** | **Axis – Sacrum** | **Extension, reinforces front of annulus fibros sis** |
| **Posterior Longitudinal** | **Axis – Sacrum** | **Flexion & reinforces back of annulus fibrosis** |
| **Ligamentum Flavum** | **Axis – Sacrum** | **Flexion** |

| | | |
|---|---|---|
| Supraspinous | Thoracic & Lumbar | Flexion |
| Interspinous | Lumbar | Flexion |
| Intertransverse | Lumbar | Lateral flexion |
| Iliolumbar | Sacroiliac joints | Stability & some motion |
| Sacroiliac | Sacroiliac joints | Stability & some motion |
| Sacrospinous | Sacroiliac joints | Stability & some motion |
| Sacrotuberous | Sacroiliac joints | Stability & some motion |

Over time, these, or really any, ligaments can lose strength and elasticity like other elastic tissues of the body. The ligamentum flava can also thicken as well as buckle inward toward the spinal column. This can create a painful condition of a narrowing of the spinal canal (spinal stenosis). If the ligamentum flavum buckles to the point that it compresses a spinal nerve, the person may experience: weakness, numbness, localized pain, radiating pain: depending on the location, the pain could radiate into the shoulders, arms, ribs or legs.

A sprain is the stretching or tearing of a ligament. A sprain often results from a fall or sudden twist, or a blow to the body that forces a joint out of its normal position. All of these conditions stretch one or more ligaments beyond their normal range of movement, causing injury. Injury to any ligament results in a spasm immobilizes the muscles in the injured area. This spasm acting as a splint to protect the ligaments and related joints from further damage. Usually, ligament injuries occur from a traumatic event, and depending on the severity of the injury, they can take from six weeks to a full year to heal.

## 4. <u>The Back Muscles</u>

The muscles of the back are divided into three groups – superficial, intermediate and intrinsic:

**Superficial** – associated with movements of the shoulder.
**Intermediate** – associated with movements of the thoracic cage.
**Deep** – associated with movements of the spine.

**The superficial back muscles** are situated underneath the skin and superficial fascia. They originate from the vertebral column and attach to the bones of the shoulder – the clavicle, scapula and humerus, and are thus associated with movements of the upper limb. The muscles in this group are the **trapezius, latissimus dorsi, levator scapulae and the rhomboids.** The trapezius and the latissimus dorsi lie the most superficially, with the trapezius covering the rhomboids and levator scapulae.

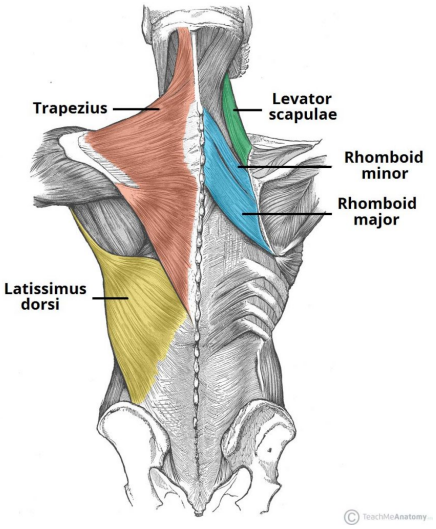

The intermediate group contains two muscles – the **serratus posterior superior** and **serratus posterior inferior**. These muscles run from the vertebral column to the ribcage, and assist with elevating and depressing the ribs. They are thought to have a slight respiratory function.

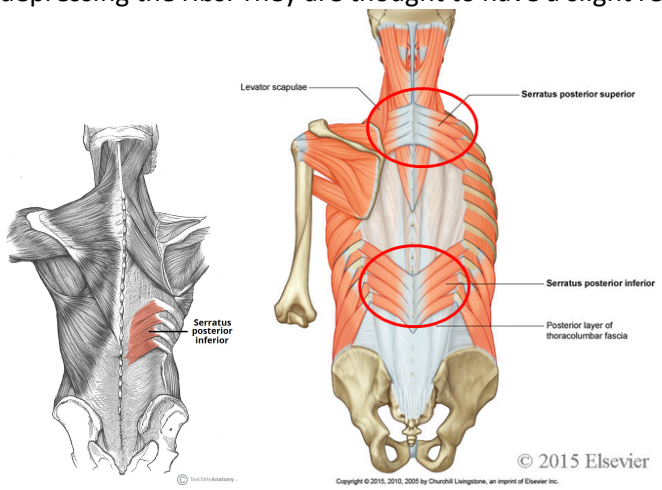


**The Deep or Intrinsic Back Muscles**

The deep muscles develop embryologically in the back, and are thus described as intrinsic muscles. The superficial and intermediate muscles do not develop in the back, and are classified as extrinsic muscles. The deep muscles of the back are well-developed, and collectively extend from the sacrum to the base of the skull. They are associated with the movements of the vertebral column and the control of posture. The muscles themselves are covered by deep fascia, which plays a key role in their organization.

Anatomically, the deep back muscles are also divided into three layers that are also called superficial, intermediate and deep. I know, right? ☺

**Superficial**

The superficial muscles are also known as the spinotransversales. There are two muscles in this group – **splenius capitis** and **splenius cervicis**. They are both associated with movements of the head and neck.

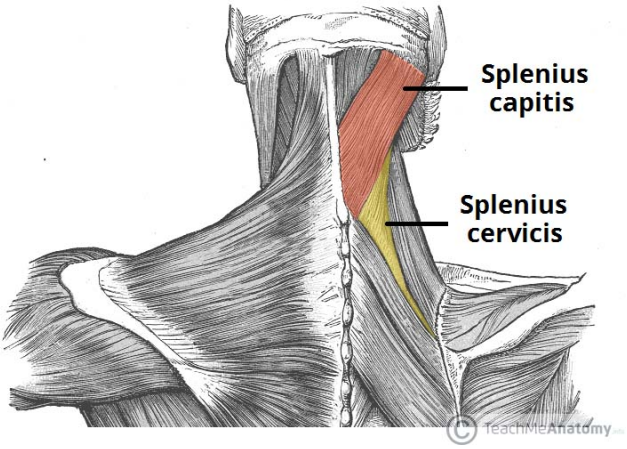


They are located on the posterolateral aspect of the neck, covering the deeper neck muscles.

**Intermediate**

There are three intermediate intrinsic back muscles – **the iliocostalis, longissimus and spinalis**. Together these muscles form a column, known as the erector spinae. The erector spinae are situated posterolaterally to spinal column, between the vertebral spinous processes and the costal angle of the

ribs. All three muscles can be subdivided by their superior attachments (into lumborum, thoracic, cervicis and capitis). They also all have a common tendinous origin.

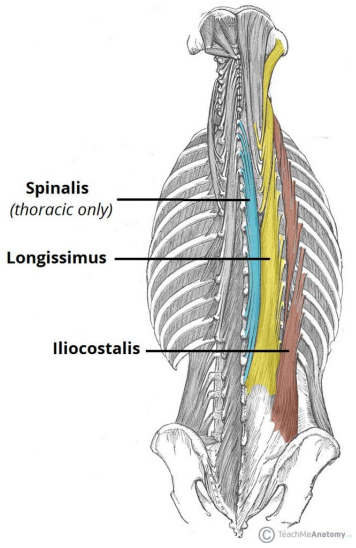


The erector spinae

**Deep**

The deep intrinsic muscles are located underneath the erector spinae. They are a group of short muscles associated with the transverse and spinous processes of the vertebral column.

There are three major muscles in this group – the **semispinalis, multifidus and rotatores**.

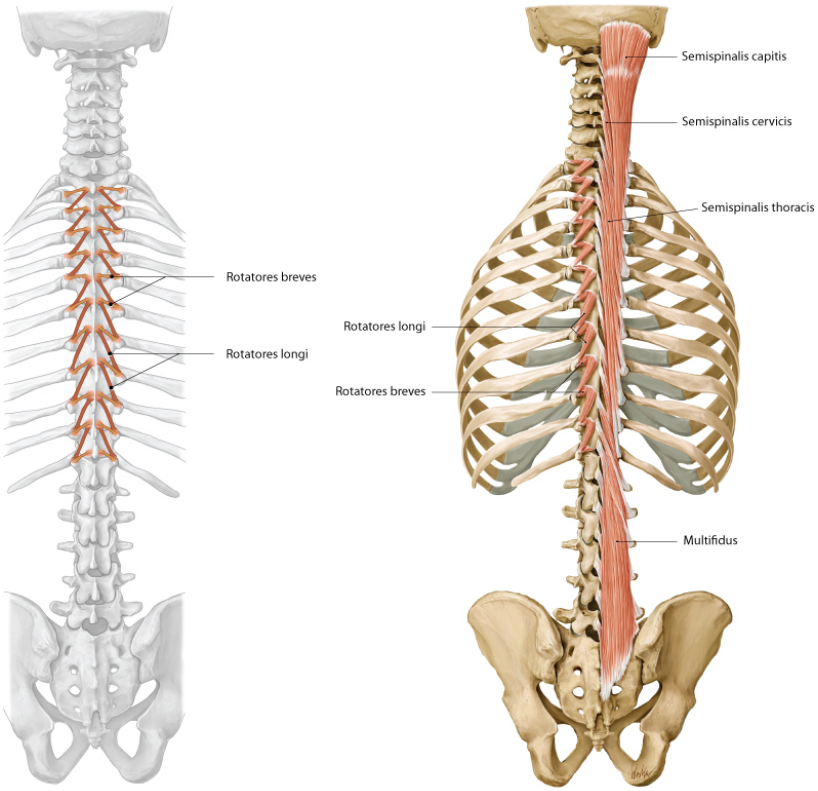

The semispinalis is the most superficial of the deep intrinsic muscles. It can be divided by its superior attachments into thoracic, cervicis and capitis. The multifidus is located underneath the semispinalis muscle. It is best developed in the lumbar area. And the rotatores are most prominant in the thoracic region. There are as well minor deep intrinsic muscles called the **interspinales, intertransversari and the levatores costarum.**

Any aspect of this vast and complex musculature of the back can sustain injury. A strain refers to an injury to either a muscle or tendon. With a back strain, the muscles and tendons that support the spine are usually overstretched or torn. Strain can also be caused by a single instance of improper lifting or any overstressing of the back muscles. A chronic strain usually results from overuse involving prolonged, repetitive movements or positions of the muscles and tendons. Several factors put a person at greater risk for a back strain, including excessively curving the lower back, having weak back or abdominal muscles, and tight hamstrings. Symptoms of a strain include:

- Pain that worsens with movement
- Muscle cramping or spasms
- Decreased function and/or range of motion of the joint (difficulty walking, bending)

And in some cases, the person may feel a pop or tear at the time of the injury.

5. **<u>The Tendons</u>**

A tendon is a tough band of fibrous connective tissue usually connecting muscles to bones. Tendons can withstand some tension. They can be torn but most commonly they become irritated causing pain.

Tendinopathy, more commonly referred to as tendonitis, is a condition in which a tendon becomes painfully inflamed. It is usually experienced as pain, stiffness, and loss of strength in the affected area. The pain may get worse upon use, and be quite painful and stiff upon rising the morning. The area may be tender, red, warm with inflammation or swollen. Tendon injury is often the result of overuse or overexertion. Injuries to a tendon can be very slow to heal, as there is very little blood circulation in this connective tissue. Treatment often includes rest and hot compresses to increase blood flow to the area. Because many tendons are attached to the spinal column, their inflammation could directly press upon nerve tissue in the spine as well.

All of these various tissues work in conjunction with one another, and can be considered the 'spinal system' including their effects on the nerves and blood flow. The close-packed nature of each spinal segment influences the severity of the symptoms that are experienced if any of the above structures are damaged or moved out of place.